



# A Rare Case of Colonic Schwannoma

## Nadir Bir Kolonik Schwannoma Olgusu

© Ayberk Dursun<sup>1</sup>, © Bengi Balcı<sup>1</sup>, © Emel Ebru Pala<sup>2</sup>, © Bülent Çalık<sup>1</sup>

<sup>1</sup>İzmir Tepecik Training and Research Hospital, Clinic of General Surgery, İzmir, Turkey

<sup>2</sup>İzmir Tepecik Training and Research Hospital, Clinic of Pathology, İzmir, Turkey

### ABSTRACT

Schwannomas are tumors originating from schwann cells in the nervous system. Colonic location is rarely seen and there are a few case reports published in the literature. We report a 53 year-old female who presented with abdominal pain, nausea, diarrhea ongoing for 2 years. Computer Tomography scan revealed a solid mass in size of 12.5x8 cm originating from the ascending colon and multiple lymphadenopathies in surrounding area. The patient underwent extended right hemicolectomy. The histopathological examination demonstrated a benign colonic schwannoma. Preoperative diagnosis of Colonic schwannoma seems to be difficult and usually schwannoma is diagnosed in the postoperative pathological examinations.

**Keywords:** Colonic schwannoma, gastrointestinal stromal tumor, schwannoma

### ÖZ

Schwannomlar, sinir sistemindeki schwann hücrelerinden kaynaklanan tümörlerdir. Kolonik yerleşim nadir görülür ve literatürde yayınlanmış az sayıda olgu sunumu vardır. İki yıldır devam eden karın ağrısı, bulantı ve ishal şikayeti ile başvuran 53 yaşında bir kadın hastayı sunuyoruz. Bilgisayar Tomografi taramasında, çıkan kolonda 12.5x8 cm boyutlarında solid bir kitle ve çevresindeki alanda birden fazla şüpheli lenfadenopati saptandı. Hastaya genişletilmiş sağ hemikolektomi yapıldı. Histopatolojik inceleme sonucunda benign kolonik schwannoma tanısı kondu. Kolonik schwannomanın preoperatif tanısı zordur. Schwannoma tanısı genellikle postoperatif patolojik inceleme sonucu konulmaktadır.

**Anahtar Kelimeler:** Kolonik schwannom, kolon tümörü, schwannom

## Introduction

Schwannomas are tumors originating from schwann cells in the nervous system.<sup>1</sup> Schwannoma of the gastrointestinal tract is extremely rare.<sup>2</sup> It is most commonly seen in the stomach and small intestines.<sup>3,4</sup> Colonic localization is seen rare and there are a few case reports in the literature. High mitotic index, the size of tumor and Ki-67 index are used as malignancy features of schwannoma on pathological examination. Preoperative diagnosis is extremely difficult and patients are usually diagnosed after pathological examinations.

## Case Report

A 53 year-old female applied to outpatient clinic with the complaints of abdominal pain, diarrhea and nausea

ongoing for 2 years. The patient was previously diagnosed with diabetes mellitus and chronic hypertension and did not have any history of previous abdominal surgery. On physical examination, the patient had abdominal defense and suspicious intra-abdominal mass with palpation in the right lower quadrant. Laboratory results were found to be normal. Computer tomography (CT) scan revealed a solid mass in size of 12.5x8 cm originating from the ascending colon and multiple lymphadenopathies in surrounding area (Figure 1). There were no signs of solid organ metastasis or vascular invasion. The patient underwent total colonoscopy which demonstrated a narrowing in the lumen of the ascending colon resulting from the compression of a mass originating from colonic wall but not invading mucosa of the colon.

The patient was operated with the laparoscopic extended



Address for Correspondence/Yazışma Adresi: Ayberk Dursun MD,

İzmir Tepecik Training and Research Hospital, Clinic of General Surgery, İzmir, Turkey

Phone: +90 506 540 80 06 E-mail: dursunayberk845@gmail.com ORCID ID: orcid.org/0000-0001-9187-0463

Received/Geliş Tarihi: 26.11.2019 Accepted/Kabul Tarihi: 27.12.2019

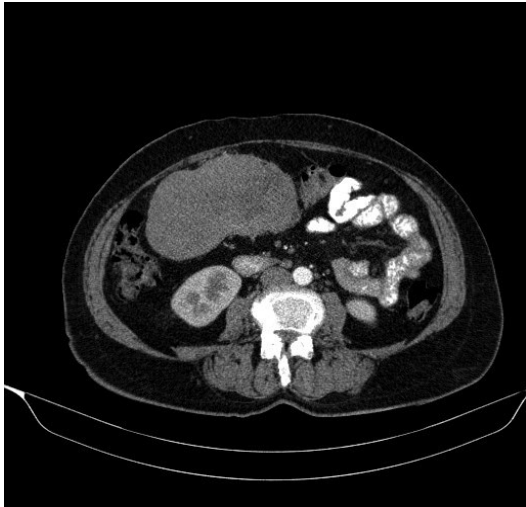
right hemicolectomy. The patient's postoperative course was uneventful and was discharged on postoperative day 6. The histopathological examination demonstrated a benign colonic schwannoma in size of 12x8x7. Extracted lymph nodes from the specimen were found to be reactive. Immunohistochemical analysis showed that the tumor was diffuse positive with S-100, and negative with desmin, caldesmon, CD117, CD34 and SMA. The proliferation index for Ki-67 was lower than 1% and the number of mitosis was 1-2/50 (Figure 2, 3, 4). Upon these results no additional treatments were recommended to the patient.

## Discussion

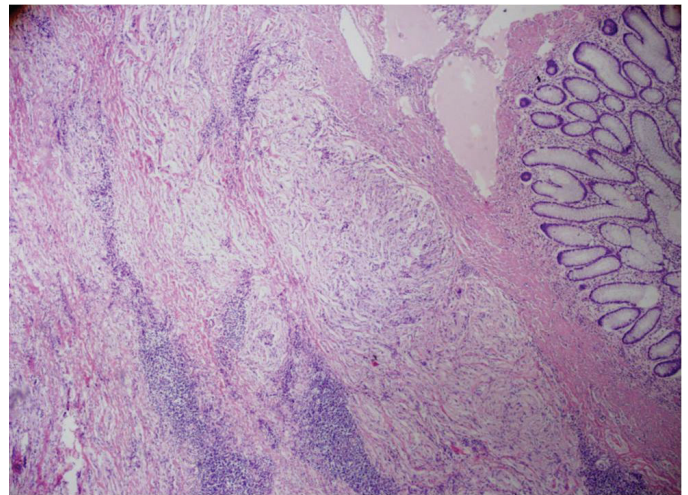
Schwannoma is a tumor derived from Schwann cells in neural crest and commonly localized in the myenteric plexus of the

peripheric nervous system.<sup>1</sup> Rarely, schwannomas can be originated from the myenteric plexus of the gastrointestinal system which are also classified as mesenchymal tumors. The incidence of schwannoma is 2-6% in gastrointestinal mesenchymal tumors and are most commonly located in the stomach (83%) and small intestines (12%).<sup>2,3,4</sup>

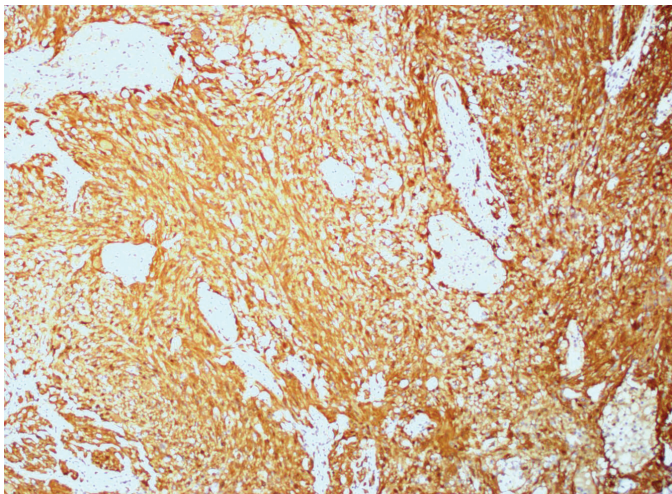
Colonic schwannoma is a rare tumor commonly reported as benign with a very low mitotic index and is frequently diagnosed as a submucosal mass or polyp.<sup>5</sup> It is reported that colonic schwannomas are usually located in the right colon (30.2%) followed by sigmoid colon, rectum, left colon and transverse colon (Table 1). Although mucosal biopsies are often inconclusive because of its submucosal location, with deep submucosal biopsies or resections, schwannoma can be differentiated from other common submucosal gastrointestinal tumors such as gastrointestinal stromal tumors (GIST), leiomyomas and neuroendocrine tumors.<sup>3,6</sup>



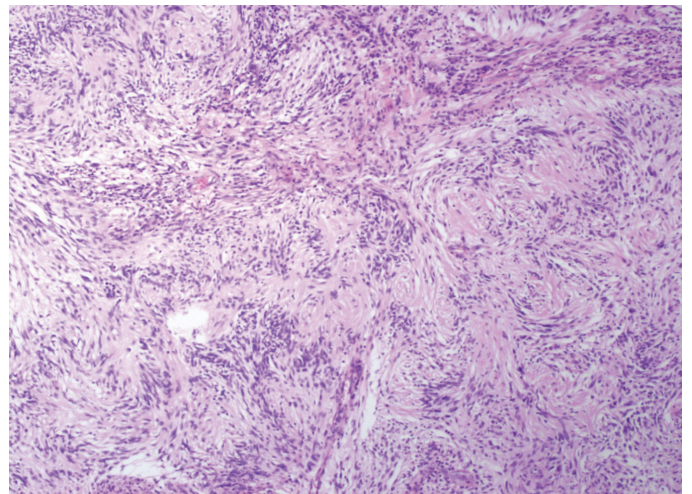
**Figure 1.** A solid mass in size of 12.5x8 cm originating from the ascending colon and multiple lymphadenopathies in surrounding area



**Figure 3.** Schwannoma areas with degenerative changes of spindle cells in the colon wall



**Figure 2.** Spindle cells diffuse positive with S-100



**Figure 4.** Palisading spindle cells and Verocay Bodies

**Table 1.** Frequencies of the schwannomas according to their localizations in the colon<sup>3</sup>

Localization	Frequency (%)
Right colon and cecum	30.2
Sigmoid colon	28.1
Rectum	21.9
Left colon	8.3
Transverse colon	5.2
Appendix	1

**Table 2.** Comparison of the schwannoma and GIST in immunohistochemical analyses<sup>1</sup>

Immuno- histochemical markers	Schwannoma	GIST
CD-117 and CD-34	Negative	Positive
S-100	Positive	Negative
SMA	Negative	Negative
GFAP	Positive	Negative
Desmin	Negative	Negative

However, GIST has a much more heterogeneous appearance on CT compared to schwannomas because of the presence of haemorrhage, necrosis, and cystic change, most of the schwannoma cases are diagnosed as GIST on CT scan.<sup>7,8</sup>

The definitive diagnosis is usually made with pathological result and immunohistochemical analysis of resected specimen.<sup>4</sup> The differential diagnosis with GIST should carefully be made by using immunohistochemical analysis including S-100, CD117 and CD34. S-100 and GFAP are characteristically found to be positive in schwannoma, whereas CD117 and SMA are negative (Table 2).

Malignant gastrointestinal schwannomas are very uncommon and associated with poor prognosis.<sup>9</sup> Malignancy features of schwannoma on pathological examination are high mitotic index, the size of tumor, high values of Ki-67 index than 10%, and the presence of hemorrhage, necrosis and ulceration on macroscopic examination.<sup>10</sup>

The prognosis of benign schwannomas was reported as excellent with complete resection of tumor and additional treatments are not recommended.<sup>11</sup>

Because of the schwannoma's rare incidence, appropriate treatment following surgery has not been well-established and long-term results are unknown.

## Ethics

**Informed Consent:** Informed consent was taken from the patient.

**Peer-review:** Internally and externally peer reviewed.

## Authorship Contributions

Surgical and Medical Practices: A.D., B.Ç., Concept: B.B., Design: B.B., Data Collection or Processing: A.D., Analysis or Interpretation: E.E.B., Literature Search: A.D., B.B., E.E.B., B.Ç. Writing: A.D., B.B.

**Conflict of Interest:** There is no conflict of interest related to any person and/or institution.

**Financial Disclosure:** No fundings were received from any person and/or institution.

## References

- Vila RD, Michaelsen MM, Bonamigo KS, Cerato NL, Garcia VC, Passos PD, Garcia AC. Gastrointestinal Schwannoma: Case Report. *Arq Bras Cir Dig* 2016;29:211.
- Tsunoda C, Kato H, Sakamoto T, Yamada R, Mitsumaru A, Yokomizo H, Yoshimatsu K, Ogawa K, Aiba M, Haga S. A case of benign schwannoma of the transverse colon with granulation tissue. *Case Rep Gastroenterol* 2009;3:116-120.
- Bohlok A, El Khoury M, Bormans A, Galdon MG, Vouche M, El Nakadi I, Donckier V, Liberale G. Schwannoma of the colon and rectum: a systematic literature review. *World J Surg Oncol* 2018;16:125.
- Baig MMAS, Patel R, Kazem MA, Khan A. Schwannoma in the ascending colon, a rare finding on surveillance colonoscopy. *J Surg Case Rep* 2019;2019:rjz046.
- Wang WB, Chen WB, Lin JJ, Xu JH, Wang JH, Sheng QS. Schwannoma of the colon: a case report and review of the literature. *Oncol Lett* 2016;11:2580-2582.
- Çalışkan C, Akgün E, Doğanavşargil B, Korkut MA. Rare tumors mimicking colorectal carcinomas. *Ege Journal of Medicine* 2009;48:101-107.
- He MY, Zhang R, Peng Z, Li Y, Xu L, Jiang M, Li ZP, Feng ST. Differentiation between gastrointestinal schwannomas and gastrointestinal stromal tumors by computed tomography. *Oncol Lett* 2017;13:3746-3752.
- Nam IC, Lee Y, Kim SH, Yoon JH, Baek HJ, Lee KH, et al. Isolated colonic Schwannoma in the ascending colon: a case report and literature review of schwannomas in the large intestine. *J Korean Soc Radiol* 2015;72:358-363.
- Wilde BK, Senger JL, Kanthan R. Gastrointestinal schwannoma: an unusual colonic lesion mimicking adenocarcinoma. *Can J Gastroenterol* 2010;24:233-236.
- Tsunoda C, Kato H, Sakamoto T, Yamada R, Mitsumaru A, Yokomizo H, Yoshimatsu K, Ogawa K, Aiba M, Haga S. A Case of Benign Schwannoma of the Transverse Colon with Granulation Tissue. *Case Rep Gastroenterol* 2009;3:116-120.
- Dickson-Lowe RA, James CL, Bailey CM, Abdulaal Y. Caecal schwannoma: a rare cause of per rectal bleeding in a 72-year-old man. *BMJ Case Rep* 2014;2014. pii: bcr2014205643.