



# Comparing Cosmetic Results of Purse-String Closure vs Conventional Linear Sutured Closure of the Stoma Wound Following Loop Ileostomy Reversal

Loop Ileostomi Sonrası Stoma Yerinin Kapatılmasında Kese Ağzı Yöntemi ile Konvansiyonel Yöntemlerin Kozmetik Sonuçlarının Karşılaştırılması

© Wafi Attaallah, © Şakir Karpuz, © Abdulla Taghiyev, © Mumin Coşkun

Marmara University Faculty of Medicine, Department of General Surgery, İstanbul, Turkey

## ABSTRACT

**Aim:** Currently, conventional linear sutured closure of the skin following loop ileostomy reversal is widely used. The purse-string closure technique has recently been described as an approach associated with less wound infection and scar formation. The primary aim of this study was to compare the cosmetic results of purse-string closure vs conventional linear sutured closure of the stoma wound following loop ileostomy reversal.

**Method:** The medical records of patients who underwent loop ileostomy closure at a single center were reviewed retrospectively. The appearance of dog-ear deformity (redundant skin) in the stoma site skin was the primary outcome used to evaluate cosmetic results.

**Results:** Twenty-five patients were included in this study. Purse-string technique was used in 10 patients and linear closure technique was performed in 15 patients. After a median follow up of 34 (12-64) months the dog-ear deformity was seen in 13 (87%) patients who underwent linear closure technique, whereas none was seen in patients who underwent purse-string closure ( $p<0.0001$ ).

**Conclusion:** Purse-string closure of the stoma wound was associated with significantly better cosmetic results compared to conventional linear sutured closure following loop ileostomy reversal.

**Keywords:** Ileostomy reversal, purse-string skin closure, linear closure, cosmetic results

## ÖZ

**Amaç:** Günümüzde loop ileostomi sonrası deri kapatılmasında konvansiyonel olarak lineer sütürler kullanılmaktadır. Son zamanlarda ise daha az yara yeri enfeksiyonu ve skar oluşumu ile ilişkili olduğu belirtilen kese ağzı şeklinde kapatma tekniği tanımlanmıştır. Bu çalışmanın amacı loop ileostomi sonrası stoma yerinin kapatılmasında kese ağzı yöntemi ile konvansiyonel yöntemlerin kozmetik sonuçlarının karşılaştırılmasıdır.

**Yöntem:** Tek merkezli olarak yapılan bu çalışmada loop ileostomileri kapatılan hastaların tıbbi kayıtları retrospektif olarak incelendi. Kozmetik sonuçların değerlendirilmesinde stoma bölgesinde dog-ear deformitesinin görülmesi primer çıkarım olmuştur.

**Bulgular:** Çalışmaya toplamda 25 hasta dahil edildi. 15 hastada kese ağzı tekniği, 10 hastada ise konvansiyonel lineer kapatma tekniği kullanıldı. Ortanca 34 (12-64) aylık takip süresi sonunda dog-ear deformitesi lineer olarak kapatılan hastaların 13'ünde (%87) izlenirken, kese ağzı yöntemi ile kapatılan hastalardan hiçbirinde izlenmemiştir ( $p<0.0001$ ).

**Sonuç:** Stoma yerinin kapatılmasında konvansiyonel lineer sütür ile kapatma yöntemine kıyasla kese ağzı yöntemi ile kapatmanın belirgin olarak daha iyi kozmetik sonuçları olduğu tespit edildi.

**Anahtar Kelimeler:** İleostomi kapatılması, kese ağzı, lineer kapatma, kozmetik sonuç

## Introduction

A temporary stoma is frequently used in the treatment of colorectal cancer, inflammatory bowel disease and diverticulitis. It is used to reduce the anastomotic leakage

and the reoperation rate particularly in very low anterior resection of rectal cancer. Many complications such as obstruction, infection, leakage, and incisional hernia can occur after stoma closure.<sup>1,2</sup>



Address for Correspondence/Yazışma Adresi: Wafi Attaallah MD,  
Marmara University Faculty of Medicine, Department of General Surgery, İstanbul, Turkey  
Phone: +90 536 818 24 55 E-mail: drwafi2003@yahoo.com ORCID ID: orcid.org/0000-0002-3179-4144  
Received/Geliş Tarihi: 31.05.2018 Accepted/Kabul Tarihi: 13.07.2018

After stoma closure, surgical site infection is also a frequent complication, with a reported incidence rates up to 40% in patient with conventional linear sutured closure of the stoma wound.<sup>3,4</sup>

The treatment of surgical site infection (SSI) requires wound drainage, cleaning, and, in some cases, antibiotics. However, the cosmetic results are not satisfactory and the healing time is extended.<sup>5,6</sup> The optimal stoma site skin-closure technique has not yet been established. Currently, conventional linear sutured closure of the skin following stoma reversal is widely used.

The circumferential purse-string approximation technique, introduced by Banerjee, after an ileostomy closure has been associated with less wound infection and scar formation, as well as with better cosmetic results.<sup>7</sup>

The primary aim of this retrospective study is to compare the cosmetic outcomes of the circumferential purse-string approximation technique and conventional linear sutured closure of the skin following loop ileostomy closure.

## Materials and Methods

### Patients

We retrospectively reviewed the medical records of patients who underwent loop ileostomy closure at Marmara University Hospital in Turkey between February, 2012 and May, 2016. Medical charts were reviewed for patient demographics, including age, gender, past medical history, such as the presence of diabetes, chronic obstructive pulmonary disease, cardiovascular disease, liver dysfunction, alcohol consumption and smoking status.

Patients were included if they had reversal of a loop ileostomy. The exclusion criteria were death, loss to follow up or presence of another stoma at the time of the study.

### Operative Techniques

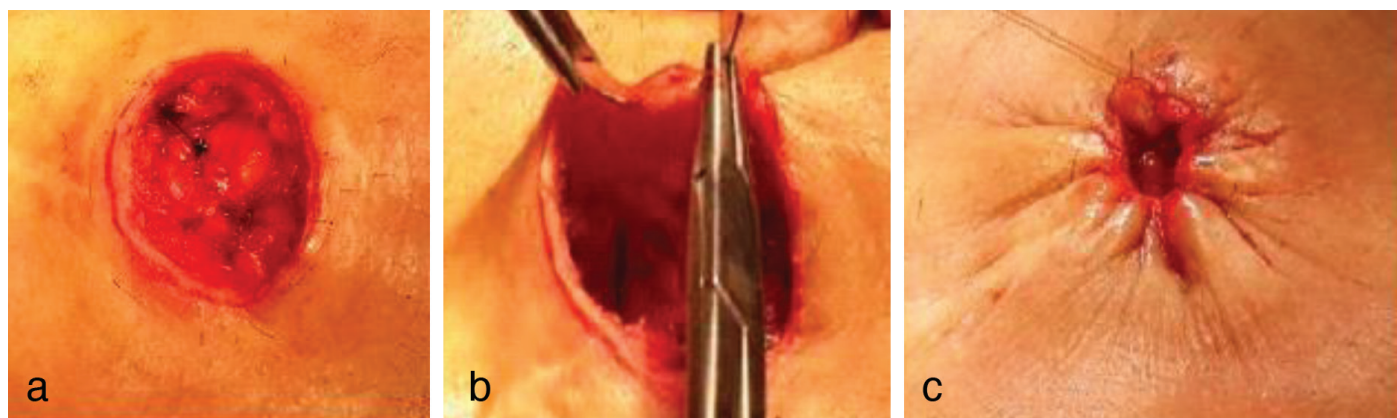
In patients who underwent the linear technique, the incision was made in a spindle-shape fashion, with a cylindrical stoma takedown. The anastomosis was accomplished by a hand-sewn or stapled anastomosis after resection of a segment of the small bowel or with the fold over technique. The fascia was closed with figure-of-8 stitches using 1-0 polyglactin. The skin was closed with 3 or 4 interrupted stitches using 3-0 polypropylene.

In patients who underwent the purse-string technique, a circular incision was made 1 to 2 mm lateral to the mucocutaneous junction. The stoma takedown and anastomosis were performed in the same manner as in the former group. The skin was closed using a purse-string subcuticular continuous suture with 3/0 monocryl, leaving an open orifice of about 5 mm (Figures 1a, b, c). The cosmetic appearance of the scar was evaluated after inviting the patients for follow up visits. Photos of the stoma site were taken during the visit for evaluation the appearance of the scar. The appearance of dog-ear deformity (redundant skin) (Figure 2) in the stoma site skin was the objective criteria we used in this study to evaluate the cosmetic results. Surgical site infection was considered as any superficial or deep infection in the wound that occurred up to 1 month of the postoperative period.<sup>8</sup> The clinical findings used to diagnose surgical site infection were purulent secretion, pain, erythema, and warmth.<sup>9,10</sup>

This study was approved by the Institutional Review Board of Marmara University (approval number: 09.2018.001) and written informed consent was obtained from all the patients.

### Statistical Analysis

All data were analyzed using SPSS 23.0 statistical software package (SPSS, Inc., Chicago, IL, USA). Nominal variables



**Figure 1.** a-c) Surgical procedure of the purse-string skin closure. Following ileostomy reversal. (a) A circular incision was made around the mucocutaneous junction, (b) A circumferential subcuticular stitch using 3-0 absorbable material was placed around the circumstomal incision, (c) Purse-string final wound

were analyzed using the  $\chi^2$  test or Fisher exact test. Ordinal variables were analyzed using Student's t-test or Mann-Whitney U test. A p value of less than 0.05 was considered to indicate statistical significance.

## Results

Between February 2012 and May 2016, all patients who underwent loop ileostomy closure in the Clinic of General Surgery Marmara University Hospital were contacted by phone. Among a total of 43 patients, 4 were deceased, 2 had stoma reopened and twelve were lost to follow up. Twenty five patients were included in this study. The median age of the 25 patients was 58 (24-77) years, and 21 (84%) were male. The primary operation of eleven (44%) patients were colorectal cancer surgery. The remaining fourteen patients were operated for benign diseases. Laparoscopic surgery was performed in 4 (16%) patients during the primary operation. The median follow up time for the patients was 34 (12-64) months. Purse-string technique was used in 10 patients and linear closure technique was performed in 15 patients. The two groups were comparable regarding patients' characteristics (Table 1). Fifteen consecutive patients who were underwent loop ileostomy closure between February 2012 and March 2014, underwent conventional linear sutured closure of the skin following stoma reversal. However after March 2014 purse-string technique was used in 10 (71%) out of 14 consecutive patients.

After a median follow up of 34 months the dog-ear deformity was seen in 13 (87%) patients who underwent linear closure technique (Figure 3), whereas none was seen in patients who underwent purse-string closure ( $p<0.0001$ ) (Figure 4). One patient (7%) in the linear closure group was diagnosed with surgical site infection based on retrospectively collected data. None of the patients in the purse-string closure group was diagnosed with surgical site infection ( $p=1.0$ ) (Table 1).

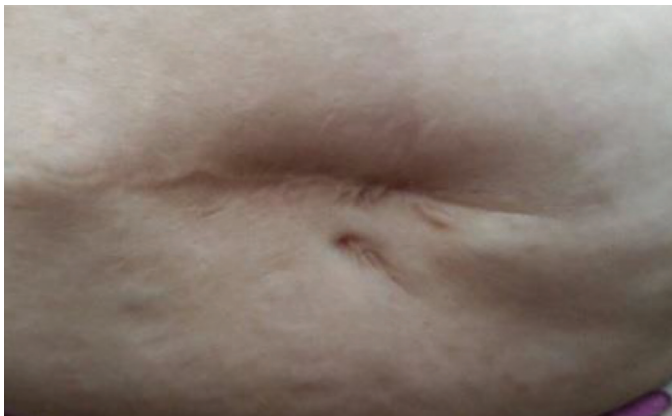

Figure 2. The appearance of dog-ear deformity (redundant skin)

## Discussion

This study showed that significantly higher rates of dog-ear deformity (87%) occurred in patients who underwent linear sutured closure of the stoma wound following loop ileostomy reversal ( $p<0.0001$ ). No dog-ear deformity occurred after purse-string closure of the stoma wound.

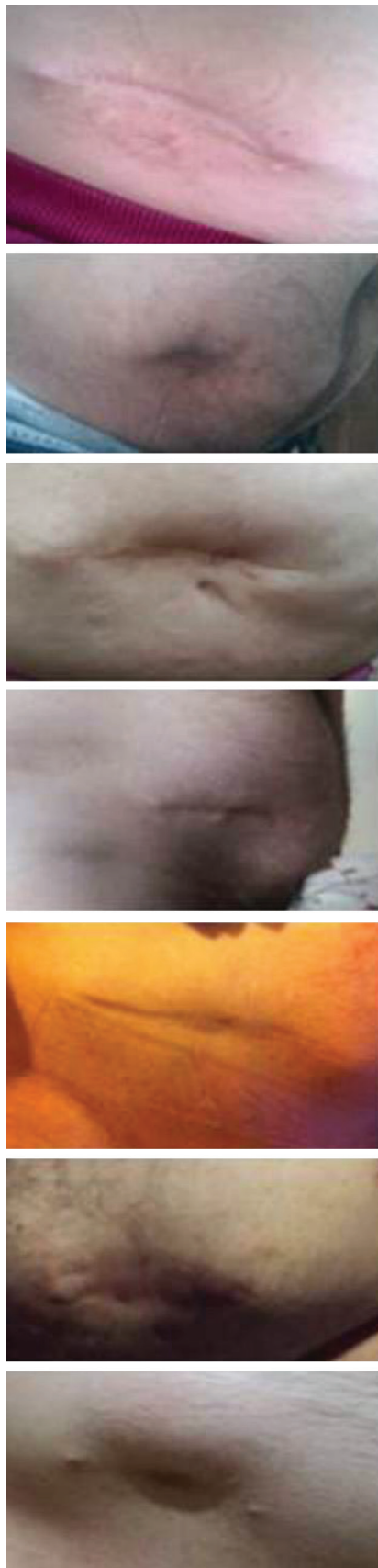Conventionally, outcome assessments in colorectal cancer include mortality, morbidity, disease recurrence, and long-term survival. However, patient-reported outcomes (e.g., cosmetic results) are now also regarded as key measurements in assessing outcomes of interventions.<sup>11</sup>

Cosmetic results are considered to be important aspects for patients. However, the optimal skin-closure technique following loop ileostomy reversal has not yet been established.<sup>6</sup> Currently, conventional linear sutured closure of the skin following loop ileostomy reversal is widely used.<sup>5</sup>

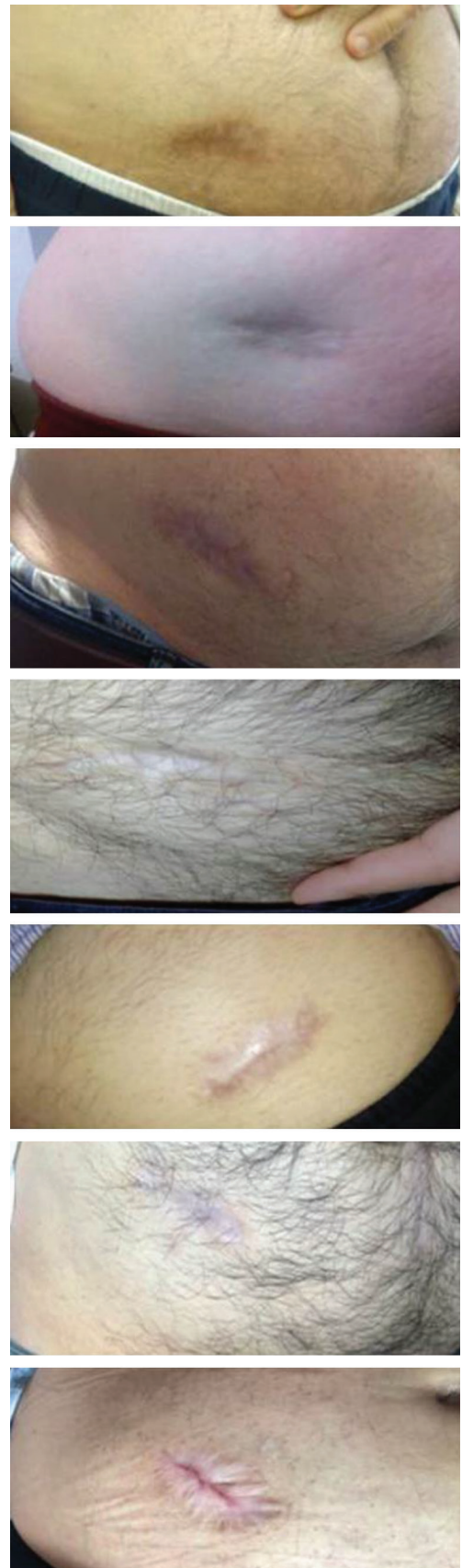Table 1. Patients characteristics and outcomes

	Linear technique n=15	Purse-string technique n=10	p value
Age (median) years	58 (24-75)	55 (30-75)	0.70
Gender			
Male	13 (87%)	8 (80%)	1.0
Female	2 (13%)	2 (20%)	
Cancer diagnosis	7 (47%)	4 (40%)	1.0
Adjuvant chemotherapy	1 (7%)	4 (40%)	0.12
Adjuvant radiotherapy	1 (7%)	2 (20%)	0.54
Ileostomy duration (months)			
Median time from stoma creation to closure (months)	7 (2-36)	5 (2-15)	1.0
Index operation laparoscopic surgery	4 (27%)	0 (0%)	0.13
<b>Comorbid disease</b>			
Diabetes mellitus	2 (13%)	3 (30%)	0.36
Hypertension	3 (20%)	1 (10%)	0.63
Coronary artery disease	1 (7%)	1 (10%)	1.0
Renal failure	0 (0%)	1 (10%)	0.40
Smoking	6 (40%)	5 (50%)	0.70
Alcohol consumption	1 (7%)	0 (0%)	1.0
Duration of follow-up (mo), median (range)	40 (17-64)	25 (12-37)	<0.0001
Dog-ear deformity	13 (87%)	0 (0%)	<0.0001
Wound infection	1 (7%)	0 (0%)	1.0





**Figure 3.** The appearance of dog-ear deformity in patients with linear closure technique



**Figure 4.** The appearance of the wound in the patients with purse-string closure technique

This study fills this gap of the less discussed issue of skin closure technique and highlights the better cosmetic results of purse-string skin closure technique.

Major limitations of this study were the small sample size and the retrospective design of the study.

Surgical site infection is one of the most common complications that can occur after stoma closure. Reports have described differences in the incidence of wound infection depending on the skin closure technique.

Different types of closure techniques were attempted to try to reduce the high rates of wound infection related to stoma closure.

Although associated with a lower risk of infection, secondary closure has higher costs, long healing time and its cosmetic results are not pleasant.

Two prospective randomized studies compared the incidence of infections after primary and secondary closure. Surgical site infections occurred in 20% and 36% of cases that underwent primary closure, in comparison with 10% and 5% in the secondary closure group.<sup>12,13</sup>

Depending on the closure technique, the surgical site infection rate ranges between 0% and 41%. Primary linear closure, secondary closure, and purse-string closure have been introduced as stoma closure techniques, but there is no consensus on the ideal closure technique for a stoma wound. In one prospective non-randomized trial, the surgical site infection rate was 21.4% after primary linear closure, whereas no SSIs occurred in the circumferential purse-string group.<sup>14</sup>

A randomized clinical trial of short-term outcomes following purse-string versus conventional closure of ileostomy wounds performed by Reid et al.<sup>15</sup> randomly assigned 61 patients, 31 and 30 in each group. The only statistically significant difference found was a decrease in surgical site infection in the purse-string closure group (12% vs 2%,  $p=0.005$ ).

The advantage of the circumferential purse-string is that, until granulation tissues grow and the skin is epithelialized, small skin defect areas act as natural drainage pathways that prevent wound infection.<sup>16</sup>

Camacho-Mauries et al.<sup>5</sup> randomized 2 groups, comparing purse-string closure vs conventional linear closure. The SSI rate for the conventional linear closure group was 36.6% ( $n=11$ ) vs 0% in the purse-string closure group ( $p<0.0001$ ).

In this study, the infection rate in the conventional linear closure group was 7% vs 0% in the purse-string closure group ( $p=1.0$ ). The difference between the two groups was not significant which may be due to the small sample size and the retrospective design of the study.

The cosmetic outcomes are very important for patients.

Camacho-Mauries et al.<sup>5</sup> reported that the results achieved with the purse-string technique were highly appreciated. They used a visual analog scale with a score from 0 to 10 (0 being the lowest and 10 the highest grade in cosmetic scar perception of the patient) to evaluate the post-operative cosmetic appearance of the scar. In the purse-string closure group, 93% of the scores ranged from 8 to 10, whereas, in the linear closure group, 57% had scores of 4, 5, and 7. In the same study patient satisfaction levels were graded by using a scale from 1 to 4, 1 being very unsatisfied and 4 very satisfied. Seventy percent of the patients with purse-string closures were very satisfied in comparison with 20% in the other group ( $p=0.0001$ ). The visual analog scale and patient satisfaction levels are considered as subjective tools to evaluate the cosmetic results. However, in this study we used the dog-ear deformity as an objective criteria to evaluate the cosmetic results.

Camacho-Mauries et al.<sup>5</sup> reported the cosmetic results using scales at 6 months after surgery. Whereas in this study cosmetic results were evaluated after a longer [34 (12-64) months] follow up period.

Another study reported a trend towards better cosmetic results for circumferential subcuticular wound approximation compared to primary closure<sup>17</sup> and significantly higher mean patient satisfaction score was reported in the circumferential subcuticular wound approximation group compared to the primary closure group.

Klink et al.<sup>18</sup> reported that patients who underwent a circumferential subcuticular wound approximation found that while the initial circular scar might be unappealing, final scar formation occurred along natural skin tension lines, producing a cosmetically pleasant scar.

This study showed that after March 2014, purse-string technique was used in 10 (71%) out of 14 consecutive patients in our hospital. This means that purse string closure technique has recently become more preferred by surgeons in our hospital due to its lower rates of SSIs as well as its better long-term cosmetic results.

Purse-string closure of the stoma wound was associated with a significantly better cosmetic results compared to conventional linear sutured closure following loop ileostomy reversal.

## Ethics

**Ethics Committee Approval:** This study was approved by the Institutional Review Board of Marmara University (approval number: 09.2018.001).

**Informed Consent:** Informed consent was obtained from all the patients.

**Peer-review:** External and internal peer-reviewed.

### Authorship Contributions

Surgical and Medical Practices: W.A., Ş.K., A.T., M.C., Concept: W.A., Ş.K., A.T., M.C., Design: W.A., Ş.K., A.T., M.C., Data Collection or Processing: W.A., Ş.K., A.T., M.C., Analysis or Interpretation: W.A., Ş.K., A.T., M.C., Literature Search: W.A., Ş.K., A.T., M.C., Writing: W.A., Ş.K., A.T., M.C.

**Conflict of Interest:** No conflict of interest was declared by the authors.

**Financial Disclosure:** The authors declared that this study received no financial support.

### References

- Alvandipour M, Gharedaghi B, Khodabakhsh H, Karami MY. Purse-String Versus Linear Conventional Skin Wound Closure of an Ileostomy: A Randomized Clinical Trial. *Ann Coloproctol* 2016;32:144-149.
- Tan WS, Tang CL, Shi L, Eu KW. Meta-analysis of defunctioning stomas in low anterior resection for rectal cancer. *Br J Surg* 2009;96:462-472.
- Sutton CD, Williams N, Marshall LJ, Lloyd G, Thomas WM. A technique for wound closure that minimizes sepsis after stoma closure. *ANZ J Surg* 2002;72:766-767.
- Llaguna OH, Avgerinos DV, Lugo JZ, Matatov T, Abbadessa B, Martz JE, Leitman IM. Incidence and risk factors for the development of incisional hernia following elective laparoscopic versus open colon resections. *Am J Surg* 2010;200:265-269.
- Camacho-Mauries D, Rodriguez-Diaz JL, Salgado-Nesme N, González QH, Vergara-Fernández O. Randomized Clinical Trial of Intestinal Ostomy Takedown Comparing Pursestring Wound Closure vs Conventional Closure to Eliminate the Risk of Wound Infection. *Dis Colon Rectum* 2013;56:205-211.
- Dusch N, Goranova D, Herrle F, Niedergethmann M, Kienle PN. Randomized controlled trial: comparison of two surgical techniques for closing the wound following ileostomy closure: purse string vs direct suture. *Colorectal Dis* 2013;15:1033-1040.
- Banerjee A. Pursestring skin closure after stoma reversal. *Dis Colon Rectum* 1979;40:993-994.
- Matthaiou DK, Peppas G, Falagas ME. Meta-analysis on surgical infections. *Infect Dis Clin North Am* 2009;23:405-430.
- Gardner SE, Frantz RA, Doebebling BN. The validity of the clinical signs and symptoms used to identify localized chronic wound infection. *Wound Repair Regen* 2001;9:178-186.
- Cutting KF, White RJ. Criteria for identifying wound infection- revisited. *Ostomy Wound Manage* 2005;51:28-34.
- Sprangers MA. Quality-of-life assessment in oncology: achievements and challenges. *Acta Oncol* 2002;41:229-237.
- Lahat G, Tulchinsky H, Goldman G, Klauzner JM, Rabau M. Wound infection after ileostomy closure: a prospective randomized study comparing primary vs. delayed primary closure tech-niques. *Tech Coloproctol* 2005;9:206-208.
- Vermulst N, Vermeulen J, Hazebroek EJ, Coene PP, van der Harst E. Primary closure of the skin after stoma closure. Management of wound infections is easy without (long-term) complications. *Dig Surg* 2006;23:255-258.
- Sang Il Yoon, Sun Mi Bae, Hwan Namgung, Dong Guk Park. Clinical Trial on the Incidence of Wound Infection and Patient Satisfaction After Stoma Closure: Comparison of Two Skin Closure Techniques *Ann Coloproctol* 2015;31:29-33.
- Reid K, Pockney P, Pollitt T, Draganic B, Smith SR. Randomized clinical trial of short-term outcomes following pursestring versus conventional closure of ileostomy wounds. *Br J Surg* 2010;97:1511-1517.
- Lee JR, Kim YW, Sung JJ, Song OP, Kim HC, Lim CW, Cho GS, Jung JC, Shin EJ. Con-ventional linear versus purse-string skin closure after loop ileostomy reversal: comparison of wound infection rates and operative outcomes. *J Korean Soc Coloproctol* 2011;27:58-63.
- Milanchi S, Nasser Y, Kidner T, Fleshner P. Wound infection after ileostomy closure can be eliminated by circumferential subcuticular wound approximation. *Dis Colon Rectum* 2009;52:469-474.
- Klink CD, Wünschmann M, Binnebösel M, Alizai HP, Lambert A, Boehm G, Neumann UP, Krones CJ. Influence of skin closure technique on surgical site infection after loop ileostomy reversal: retrospective cohort study. *Int J Surg* 2013;11:1123-1125.