



Comparison of the Protective Effects of *Calendula officinalis* Extract and Hyaluronic Acid Anti-adhesion Barrier against Postoperative Intestinal Adhesion Formation in Rats

Ratlarda Postoperatif İntestinal Adezyon Formasyonuna karşı *Calendula officinalis* Ekstraktının ve Hyaluronik Asit Anti-adezyon Barrierinin Koruyucu Etkilerinin Karşılaştırılması

Arif Emre¹, Mehmet Sertkaya², Ali İşler¹, Abdulkadir Yasir Bahar³, Ahmet Necati Şanlı¹, Ali Özkömeç¹, Muhammed Ali İşik⁴, İlhami Taner Kale¹, Ozan Andaç Erbil⁵

¹Kahramanmaraş Sütçü İmam University Faculty of Medicine, Department of General Surgery, Kahramanmaraş, Turkey

²Viranşehir State Hospital, Clinic of General Surgery, Şanlıurfa, Turkey

³Kahramanmaraş Sütçü İmam University Faculty of Medicine, Department of Medical Pathology, Kahramanmaraş, Turkey

⁴Adıyaman University Faculty of Medicine, Department of General Surgery, Adıyaman, Turkey

⁵Gebze Fatih State Hospital, Clinic of General Surgery, Kocaeli, Turkey

ABSTRACT

Aim: Intra-abdominal adhesions that develop after abdominal surgery are still a cause of serious morbidity and mortality. This study compared the efficacy of a hyaluronic acid adhesion barrier and *Calendula officinalis* extract (COE) for inhibiting adhesion in rats.

Method: We performed laparotomies in 30 rats and induced postoperative intraabdominal adhesions using a scraping model. The animals were divided randomly into 3 groups of 10 rats each. We performed only caecal abrasions and did not apply any substance in the control group (group 1). In group 2, we performed caecal abrasion and then applied the hyaluronic acid adhesion barrier to the abraded area. In group 3, we applied COE after the caecal abrasions.

Results: There were no significant differences among the groups in terms of the macroscopic adhesion score. Histopathologically, there was a significant difference in microscopic adhesion scores between groups 1 and 2 ($p=0.044$). There was also a significant difference between groups 1 and 3 ($p=0.010$). There was no significant difference between groups 2 and 3 ($p=1$). Group 1 had the highest score for adhesions between the abdominal wall and intra-abdominal organs.

Conclusion: Both the COE and hyaluronic acid adhesion barrier significantly reduced the incidence of postoperative intra-abdominal adhesions in a rat scraping model. Although the mechanism is not clear, the COE applied in the peritoneal cavity reduced the development of adhesions. There was no significant difference between the COE and hyaluronic acid adhesion barrier in terms of preventing adhesions. Although the COE is less expensive than hyaluronic acid adhesion barrier, toxicology studies must be performed before it is used in humans.

Keywords: *Calendula officinalis*, hyaluronic acid, postoperative intra-abdominal adhesion, scraping model

ÖZ

Amaç: Abdominal cerrahi girişimler sonrası gelişebilen intraabdominal adezyonlar halen ciddi morbidite ve mortaliteye yol açmaktadır. Biz bu çalışmada hyaluronik asitli adezyon bariyeri ile *Calendula officinalis* ekstraktının (COE) deneysel adezyon modeli oluşturduğumuz ratlardaki adezyon önleyici etkisini araştırıp karşılaştırmayı amaçladık.

Yöntem: Otuz rata laparotomi yaptık ve bu ratlarda scraping model oluşturarak postoperatif intraabdominal adezyonu indükledik. Hayvanları rastgele 10 rattan oluşan 3 eşit gruba ayırdık. Kontrol grubu olan grup 1'e sadece çekal abrazyon oluşturup herhangi bir madde uygulamadık. Grup 2'ye çekal abrazyonu takiben hyaluronik asitli adezyon bariyeri uyguladık. Grup 3'e çekal abrazyonu takiben COE uyguladık.



Address for Correspondence/Yazışma Adresi: Arif Emre MD

Kahramanmaraş Sütçü İmam University Faculty of Medicine, Department of General Surgery, Kahramanmaraş, Turkey

Phone: +90 506 343 24 31 E-mail: dr.arifemre@gmail.com ORCID ID: orcid.org/0000-0002-6313-9742

Received/Geliş Tarihi: 01.03.2018 Accepted/Kabul Tarihi: 04.04.2018

ÖZ

Bulgular: Gruplar arasında makroskopik adezyon skorlaması açısından istatistiksel olarak anlamlı fark bulunamadı. Histopatolojik inceleme neticesinde mikroskopik adezyon skorları karşılaştırıldığında grup 1 ile 2 arasındaki istatistiksel fark $p=0,044$ olup anlamlıydı. Grup 1 ve 3 karşılaştırıldığında $p=0,010$ olup istatistiksel olarak anlamlıydı. Grup 2 ve 3 karşılaştırıldığında $p=1$ olup istatistiksel olarak anlamsızdı. Grup 1 abdominal duvar ve karın içi organlar arasındaki en yüksek adezyon skoru sergiledi.

Sonuç: Bu çalışma COE'nin ve hyaluronik asitli adezyon bariyerinin her ikisinde scraping modellenli ratlarda postoperatif intraabdominal adezyonların insidansını önemli derecede azalttığını göstermiştir. Mekanizma açık olmamasına rağmen peritoneal kaviteye uygulanan COE adezyon gelişimini azaltmıştır. COE ile hyaluronik asitli adezyon bariyerinin arasında adezyonu önleme açısından istatistiksel anlamlı bir fark bulunamamıştır. Ancak COE maliyet açısından hyaluronik asitli adezyon bariyerinden daha çok avantajlı olmasına rağmen insanlar üzerinde uygulanmadan önce toksikoloji çalışmaları mutlaka yapılmalıdır.

Anahtar Kelimeler: *Calendula officinalis*, hyaluronik asit, postoperatif intra-abdominal adezyon, scraping model

Introduction

Despite advances in the surgical techniques and instruments used, postoperative adhesions are unpredictable consequences of laparotomies. Postoperative intra-abdominal adhesion formation remains an important cause of morbidity and mortality. The reported incidence of adhesions in patients after laparotomy ranges from 32.6% to 90%.^{1,2} While some of these patients have no complaints, a significant proportion will develop small bowel obstruction, bowel infarction, pain, constipation, or infertility in women.³ The time required for treatment results in a loss of labour, and the costs of treatment constitute an economic loss.⁴ Several agents and barrier systems have been developed to reduce the incidence of adhesions, but none is 100% effective. The hyaluronic acid containing adhesion barrier (HAAB) is widely used worldwide.⁵ Although HAAB significantly reduced the formation of adhesions in some animal studies and clinical trials, it does not completely inhibit the formation of adhesions.

Calendula officinalis extract (COE) is an herbal agent that has anti-inflammatory, anti-oedema, and antimicrobial activities experimentally and clinically, and it is used traditionally in many parts of the world for healing wounds, peptic ulcers, and venous ulcers in the feet and legs of diabetics, preventing skin ulcers caused by radiotherapy for breast cancer, and improving colitis in inflammatory bowel disease. It was effective in the treatment of experimental oral mucositis in hamsters and in the treatment of second and third degree burns in rats.^{6,7,8,9,10,11,12,13,14,15,16,17,18,19} Long-term studies have shown that the acute and chronic toxicity of oral COE is very low in female and male rats and rarely leads to anaphylactic reactions, uterotonic effects in pregnancies, hypotension, or sedation.^{20,21,22,23} The efficacy of COE in the treatment of many different pathological conditions has been demonstrated experimentally and clinically. However, few studies have examined the anti-adhesion activity of COE. Therefore, this study investigated the efficacy of COE in

preventing postoperative intra-abdominal adhesions and compared it with the anti-adhesive efficacy of HAAB.

Materials and Methods

This study was conducted in the Animal Research Laboratory of Kahramanmaraş Sütçü İmam University after obtaining permission from the Ethics Committee. Thirty 10-12-week-old male Wistar Albino rats, each weighing 300-350 grams, were used. The animals were divided into three groups of 10 rats each. In group 1 (control group) only the scraping model was applied. In group 2, the scraping model was applied, and then HAAB was applied to the abraded bowel. Similarly, group 3 was subjected to scraping, and then the COE was applied. We used two gel preparations of The HAAB (Heine Medizin Adhesion Barrier Gel) (Figures 1, 2). The COE was obtained from the leaves of marigold plants (*Calendula officinalis*). Since a pure extract could not be obtained, it was obtained in a 4/3 ratio of pure olive oil to COE from an herbalist in Italy. A detailed biochemical analysis could not

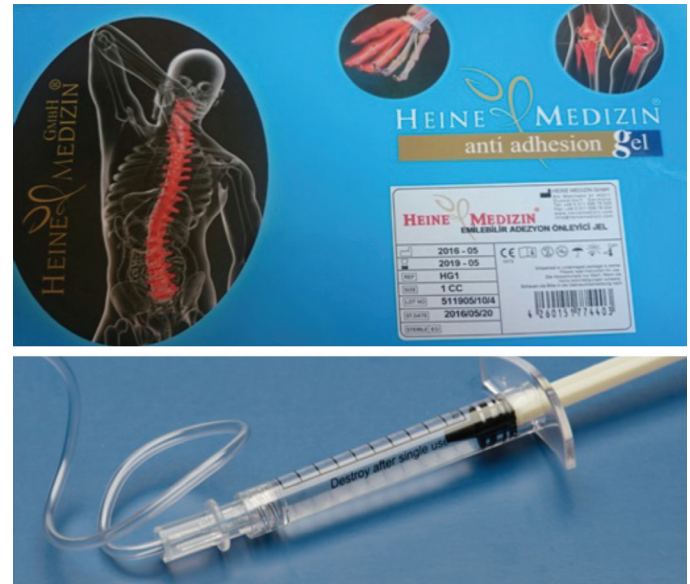

Figure 1 and 2. The hyaluronic acid adhesion barrier (Heine Medizin Adhesion Barrier Gel)

be performed. We also have no information on the altitude or region in Italy where the marigolds were grown. The rats were anaesthetised with 50 mg/kg ketamine hydrochloride (Ketalar, 50 mg/mL; intramuscular; Parke-Davis, İstanbul, Turkey) and 5 mg/kg xylazine (Xylazine-20 injection; Butler, Columbus, OH, USA).

A 3 cm midline incision was made after disinfecting the animal's abdominal skin with povidone iodide. The terminal ileum and cecum were held in a wet sponge and mobilised. Both sides of a 5–10 cm segment of the terminal ileum and cecum were irritated with a sponge until a pellet formed on the serosal surface. The scraped segment was clamped for 1 minute to create arterial transient ischemia (scraping model, Figure 3). The control group was subjected to scraping only. The scraped area was covered with 3 mL of COE in the COE group or 1 mL of adhesion barrier in the HAAB group. The abdominal incisions were closed with two layers of continuous 3/0 silk sutures. All rats were allowed to feed daily until they were sacrificed 15 days postoperatively. After sacrifice, an inverted U-shaped incision was made in the anterior abdominal wall to allow maximal exposure of the abdominal cavity. The adhesions were examined macroscopically by three independent investigators (A.E., A.I., and A.N.Ş.) and rated using the Blauer and Collins scale (Table 1). Adhesion-containing tissue samples were excised and fixed in 10% formaldehyde solution. The samples were embedded in paraffin and dehydrated. Then, 5 µm cross sections were prepared with a microtome. After staining with haematoxylin eosin, the samples were examined by the same pathologist (A.Y.B.) under light microscopy for their general structure, amount of fibroblast activity, and presence of fibrosis (Table 2). A fibrosis score for each rat was calculated according to these criteria.

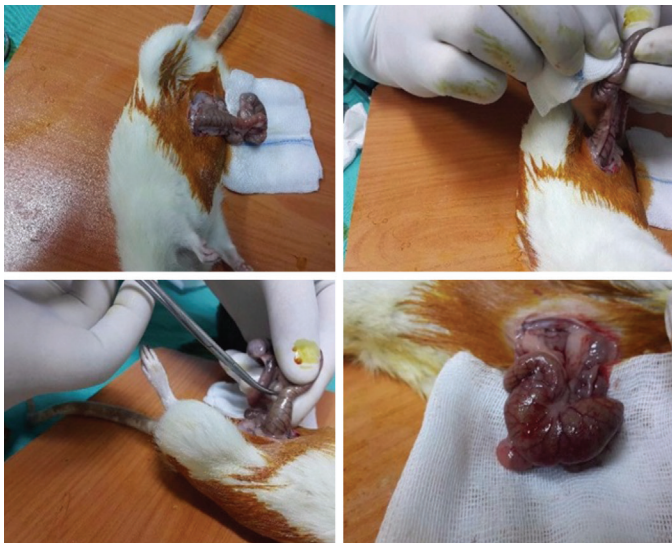

Figure 3. Scraping model

Statistical Analysis

SPSS 22.0 (IBM, Armonk, NY, USA) was used to analyse the data. The Kruskal-Wallis H-test was used for the nonparametric tests with the Monte Carlo simulation technique, and Dunn's test was used for the post hoc analyses. Quantitative variables are shown as the median (range), and categorical variables as a number. Variables were examined at the 95% confidence level, and a p value ≤ 0.05 was considered significant.

Results

All 30 rats survived until the repeat laparotomy. Table 1 shows the Blauer and Collins macroscopic adhesion scores.

Table 1. Macroscopic adhesion assessment scores for the three groups

Macroscopic findings (Blauer and Collins scale)	Calendula officinalis extract group (n=10)	Hyaluronic acid adhesion barrier group (n=10)	Control group (n=10)
No adhesions	2	3	–
Slender or narrow, easily separable adhesions	3	3	4
Thick adhesions in a limited area	3	1	2
Widespread thick adhesions	2	3	1
Widespread thick adhesions connecting organs with the anterior or posterior abdominal wall	–	–	3
Total	10	10	10

Table 2. Scores for adhesions in the three groups based on macro- and microscopic findings

Group	n	Microscopy Median (range)	Macroscopy Median (range)
Control	10	0.5 (0-2)	1.5 (0-3)
Hyaluronic acid	10	1 (1-3)	1 (0-3)
<i>Calendula officinalis</i>	10	2 (1-2)	2 (1-4)
Total	30	1 (0-3)	1.5 (0-4)
p values (overall)		0.004	0.266
Pairwise comparisons	I&II	0.044	ns
	I&III	0.010	ns
	II&III	1	ns

Kruskal–Wallis test (Monte Carlo), Dunn's post hoc test
ns: Not significant

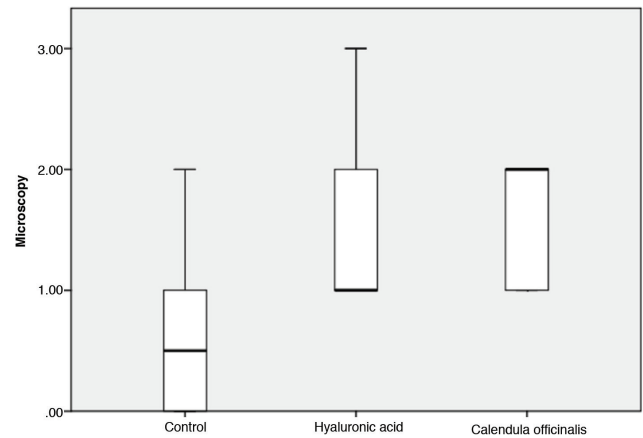
Grade 4 adhesions were seen only in three rats in the control group. The adhesions were grade 0-4 in 0, 4, 2, 1, and 3 rats in the control group, 3, 3, 1, 3, and 0 rats in the HAAB group, and 2, 3, 3, 2, and 0 rats in the COE group, respectively. There were no differences in the Blauer and Collins scores among the groups (Table 2; Figure 4). Table 3 summarises the results of the histopathological examinations in terms of the general structure of the adhesions, amount of fibroblast activity, and presence of fibrosis. Respective microscopic adhesion assessment scores of 0 to 3 were seen in 2, 4, 4, and 0 rats in the control group, 0, 6, 3, and 1 rats in the HAAB group, and 5, 4, 1, and 0 rats in the COE group (Figures 5, 6, 7). Histopathologically, the fibroliomatous tissue of the adherent areas of rats in the control group showed a decrease in fat tissue, with moderate fibrosis and fibroblast accumulation and a moderate mixed infiltration of lymphocytes, plasma cells, and polymorphonuclear leukocytes (Figure 7). The density of inflammatory cells and fibroblasts was decreased in the HAAB and COE groups (Figure 5). Comparison of the microscopic adhesion scores based on the histopathological examination revealed significant differences between groups 1 and 2 ($p=0.044$) and between groups 1 and 3 ($p=0.010$), but not between groups 2 and 3 ($p=1$). Group 1 had the highest score for adhesions between the abdominal wall and intra-abdominal organs (Table 2). COE and HAAB significantly reduced the incidence of intra-abdominal peritoneal adhesions in scraping-model rats when compared with the control group (Graph 1).

Discussion

Although the mechanism is not clear, COE administered in the peritoneal cavity significantly reduced the development

Table 3. Microscopic adhesion assessment scores in the three groups

Microscopy findings	<i>Calendula officinalis</i> group	Hyaluronic acid adhesion barrier group	Control group
No inflammation	5	—	—
Large cells, rare scattered lymphocytes and plasma cells	4	6	4
Large cells together with an increased number of lymphocytes, neutrophils, eosinophils, and plasma cells	1	3	6
Multiple and mixed inflammatory cells, micro-abscesses	—	1	—
Total	10	10	10



Graph 1. *Calendula officinalis* extract and hyaluronic acid adhesion barrier significantly reduced the incidence of intra-abdominal peritoneal adhesions in scraping-model rats when compared with the control group

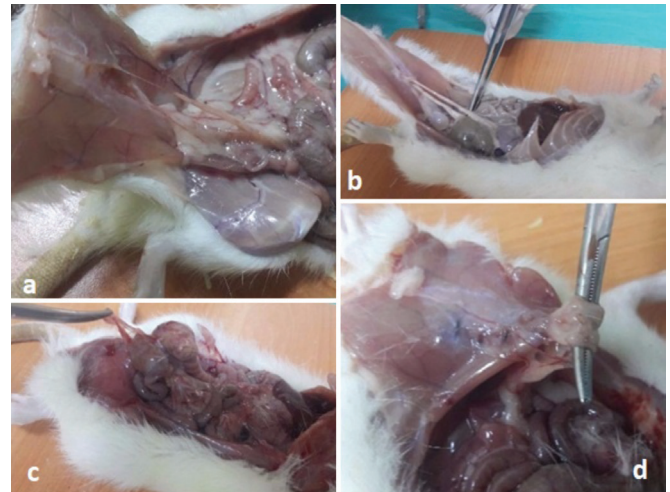


Figure 4. According to Blauer and Collins classification, at groups a) first degree, b) second degree, c) third degree, and d) fourth degree of adhesion observed

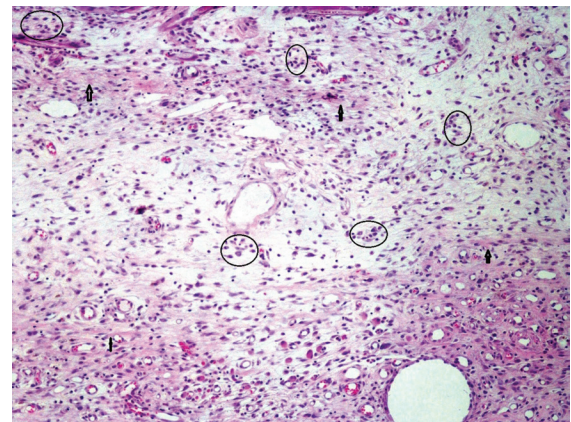


Figure 5. Omental loose fibroliomatous tissue in adherence sites has been replaced by a fat-reduced and vascularized granulation tissue. Fine fibrous bands (arrows) and scattered lymphocytes, histiocytes and plasma cell groups (intra-circle) were rated as score 1 (10x objective, hematoxylin eosin staining)

of adhesions. There was no statistical difference between COE and HAAB at preventing adhesions. COE is less expensive than HAAB. Although no adverse effects were seen in the rats treated with COE, toxicology studies must be performed before it is administered to humans. In addition, studies should examine the effects of higher doses of COE on its efficacy and toxicity. The rate of obstruction caused by abdominal surgery-induced adhesions ranges from 92.9% to 100%^{24,25} of which 60~70% are small bowel obstructions.²⁵ The relaparotomy rate due to obstruction is 29~50%.^{26,27} Other adverse effects of adhesions include enterocutaneous fistulas, intra-abdominal abscesses, chronic abdominal pain, and infertility in females due to perforations caused by intestinal obstruction.^{28,29} The prolonged hospital stays and loss of labour are other important problems. Recurrent

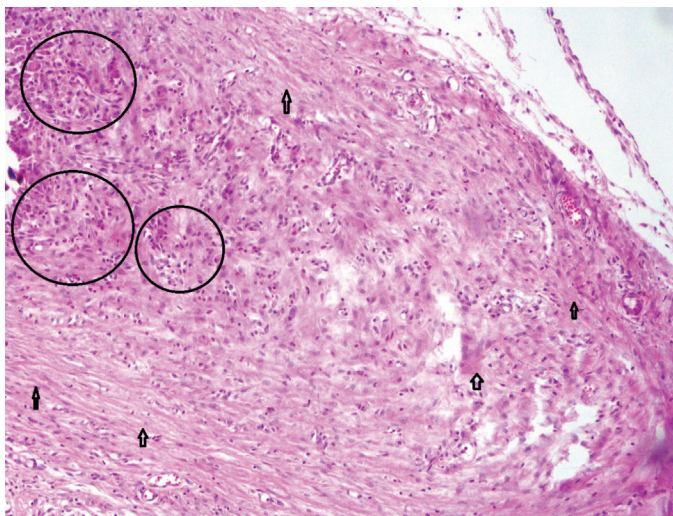


Figure 6. According to score 1, thicker fibrotic bands (arrows) and increase in inflammatory cell accumulation (inside circle) were evaluated as score 2 (10x objective, hematoxylin eosin staining)

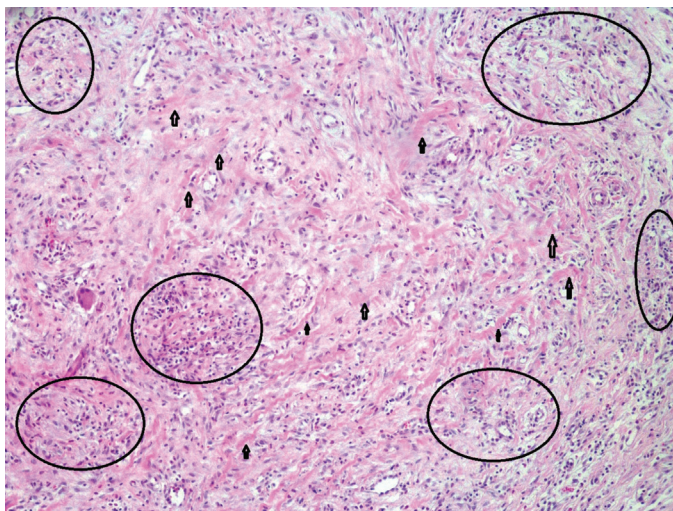


Figure 7. Intensive inflammatory cell accumulation with thick hyalinized fibrotic bands (arrows) and microabscess foci (in-the-circle) were assessed as score 3 (10x objective, hematoxylin eosin staining)

relaparotomy is also a major cause of mortality.²⁸ Although there is now a fairly good understanding of how and why adhesions occur, and there are agents to reduce adhesion formation, no agent completely prevents adhesions. Foreign bodies, blood, tissue ischemia, infection, and some chemicals that cause irritation and damage the peritoneum are all responsible for the formation of adhesions.^{30,31} There are many models of the formation of adhesions in experimental animals, including caecal scraping, caecal abrasion, uterine adhesion, peritonitis, and peritoneal defect models.^{32,33,34,35,36} We chose a scraping model that involved both ischemic and peritoneal injury (Figure 3) because ischemia and peritoneal damage frequently occur during abdominal surgery in humans. After abdominal surgery, adhesions form in an average of 7-10 days, and fibrosis with the formation of fibrotic bands occurs in 14 days. Therefore, we waited 15 days to perform the relaparotomies. There is no globally accepted scoring system for adhesions. Rather, different scoring systems are based on various parameters such as thickness, type, vascularisation, adhesiveness, density, and fibroblast density of the adhesions. The Mazuji adhesion scale ranges from 0 to 5, the Moreno score from 2 to 7, the Bigatti score from 0 to 11, and the Blauer and Collins³⁸ score from 0 to 4.^{37,38} We chose the scoring system of Blauer and Collins, which is used widely and is useful for assessing macroscopic and microscopic adhesions. Various agents have been used to prevent postoperative adhesions, including corticosteroids, antihistamines, dextran, saline, anti-cytokine agents, a recombinant tissue plasminogen activator, aprotinin, octreotide, heparin, and biorefined membranes modified from carboxymethyl cellulose, oxidised regenerated cellulose, polyethylene glycol, expanded polytetrafluoroethylene, and hyaluronic acid. However, no agent or system completely inhibits adhesions.^{39,40} Currently, hyaluronic acid preparations are among the most widely used. In this study, we compared the efficacy of HAAB at preventing postoperative intra-abdominal adhesions with that of COE, which has antimicrobial, anti-oedema, and anti-inflammatory activities. The results showed that intraperitoneal COE and HAAB both significantly reduced the development of adhesions compared with the control group. There was no difference in the inhibitory effect of the two agents. None of the rats died before the end of the experiment, suggesting that both agents were reliable in the quantities used. However, we cannot predict the effects of applying COE in different quantities. In our study, the use of HAAB within the peritoneal cavity gave results similar to those obtained in many previous studies, further demonstrating its efficacy in preventing adhesions. One of the major shortcomings of our study is the lack of a pre-application biochemical analysis of the COE obtained

from an herbalist or knowledge of the region in Italy and the altitude where the COE we used originated. Since the content of many herbal agents can vary regionally and with altitude, precise information about these variables would enhance the value of future work. In summary, the COE reduced postoperative intra-abdominal adhesion formation but did not prevent it completely. The similarity of the results using HAAB and COE suggest that new agents should be investigated for this purpose. Further studies should also investigate the effectiveness of different quantities of COE. As predicted, COE reduced the development of adhesions, although it did not prevent them completely. Although our results show that COE is effective in preventing adhesions in rats, further studies are needed before it can be used in humans.

Ethics

Ethics Committee Approval: The study was approved by the Kahramanmaraş Sütçü İmam University Local Ethics Committee (approval number: 2017/1-2 date: 03/01/2017).

Informed Consent: Consent form was filled out by all participants.

Peer-review: Externally peer-reviewed.

Authorship Contributions

Surgical and Medical Practices: A.E., A.Y.B., A.İ., A.N.Ş., A.Ö., M.A.I., Concept: A.E., M.S., A.N.Ş., Design: A.E., M.S., A.N.Ş., Data Collection or Processing: A.E., A.İ., A.N.Ş., A.Ö., M.A.I., Analysis or Interpretation: A.E., İ.T.K., O.A.E., A.Y.B., Literature Search: A.E., A.N.Ş., Writing: A.E., M.S., A.N.Ş.

Conflict of Interest: No conflict of interest was declared by the authors.

Financial Disclosure: The authors declared that this study received no financial support.

References

- Parker MC, Ellis H, Moran BJ, Thompson JN, Wilson MS, Menzies D, McGuire A, Lower AM, Hawthorn RJ, O'Brien F, Buchan S, Crowe AM. Postoperative adhesions: ten-year follow-up of 12,584 patients undergoing lower abdominal surgery. *Dis Colon Rectum* 2001;44:822-829.
- Monk BJ, Berman ML, Montz FJ. Adhesions after extensive gynecologic surgery: clinical significance, etiology, and prevention. *Am J Obstet Gynecol* 1994;170:1396-1403.
- Ellis H, Moran BJ, Thompson JN, Parker MC, Wilson MS, Menzies D, McGuire A, Lower AM, Hawthorn RJ, O'Brien F, Buchan S, Crowe AM. Adhesion-related hospital readmissions after abdominal and pelvic surgery: a retrospective cohort study. *Lancet* 1999;353:1476-1480.
- Tingstedt B, Isaksson J, Andersson R. Long-term follow-up and cost analysis following surgery for small bowel obstruction caused by intra-abdominal adhesions. *Br J Surg* 2007;94:743-748.
- Zhang G. Hyaluronic acid anti-adhesion barrier. Google Patents; 2003.
- Zitterl-Eglseer K, Sosa S, Jurenitsch J, Schubert-Zsilavecz M, Della Loggia R, Tubaro A, Bertoldi M, Franz C. Anti-oedematous activities of the main triterpene diol esters of marigold (*Calendula officinalis* L.). *J Ethnopharmacol* 1997;57:139-144.
- Ukiya M, Akihisa T, Yasukawa K, Tokuda H, Suzuki T, Kimura Y. Anti-inflammatory, anti-tumor-promoting, and cytotoxic activities of constituents of marigold (*Calendula officinalis*) flowers. *J Nat Prod* 2006;69:1692-1696.
- Tanideh N, Jamshidzadeh A, Sepehrimanesh M, Hosseinzadeh M, Koohi-Hosseinzadeh O, Najibi A, Raam M, Daneshi S, Asadi-Yousefabad SL. Healing acceleration of acetic acid-induced colitis by marigold (*Calendula officinalis*) in male rats. *Saudi J Gastroenterol* 2016;22:50.
- Sharp L, Finnilä K, Johansson H, Abrahamsson M, Hatschek T, Bergenmar M. No differences between *Calendula* cream and aqueous cream in the prevention of acute radiation skin reactions--results from a randomised blinded trial. *Eur J Oncol Nurs* 2013;17:429-435.
- Parente LM, Lino Júnior Rde S, Tresvenzol LM, Vinaud MC, de Paula JR, Paulo NM. Wound healing and anti-inflammatory effect in animal models of *Calendula officinalis* L. Growing in Brazil. *Evid Based Complement Altern Med* 2012;2012:375671.
- Okuma CH, Andrade TA, Caetano GF, Finci LI, Maciel NR, Topan JF, Cefali LC, Polizello AC, Carlo T, Rogerio AP, Spadaro AC, Isaac VL, Frade MA, Rocha-Filho PA. Development of lamellar gel phase emulsion containing marigold oil (*Calendula officinalis*) as a potential modern wound dressing. *Eur J Pharm Sci* 2015;71:62-72.
- Mishra AK, Mishra A, Verma A, Chattopadhyay P. Effects of calendula essential oil-based cream on biochemical parameters of skin of albino rats against ultraviolet B radiation. *Sci Pharm* 2012;80:669-683.
- Mishra A, Mishra A, Chattopadhyay P. Assessment of in vitro sun protection factor of *Calendula officinalis* L.(asteraceae) essential oil formulation. *J Young Pharm* 2012;4:17-21.
- Efstratiou E, Hussain AI, Nigam PS, Moore JE, Ayub MA, Rao JR. Antimicrobial activity of *Calendula officinalis* petal extracts against fungi, as well as Gram-negative and Gram-positive clinical pathogens. *Complement Ther Clin Pract* 2012;18:173-176.
- Dall'Acqua S, Catanzaro D, Cocetta V, Igl N, Ragazzi E, Giron MC, Cecconello L, Montopoli M. Protective effects of ψ taraxasterol 3-O-myristate and arnidiol 3-O-myristate isolated from *Calendula officinalis* on epithelial intestinal barrier. *Fitoterapia* 2016;109:230-235.
- Carvalho AF de, Feitosa MC, Coelho NP, Rebêlo VC, Castro JG, Sousa PR, Feitosa VC, Arisawa EA. Low-level laser therapy and *Calendula officinalis* in repairing diabetic foot ulcers. *Rev Esc Enferm USP* 2016;50:628-634.
- Buzzi M, Freitas F d, Winter Mde B. Pressure ulcer healing with Plenusdermax® *Calendula officinalis* L. extract. *Rev Bras Enferm* 2016;69:250-257.
- de Andrade M, Clapis MJ, do Nascimento TG, Gozzo Tde O, Almeida AM. Prevention of skin reactions due to teletherapy in women with breast cancer: a comprehensive review. *Rev Lat Am Enfermagem* 2012;20:604-611.
- Akhoondinasab MR, Khodarahmi A, Akhoondinasab M, Saberi M, Iranpour M. Assessing effect of three herbal medicines in second and third degree burns in rats and comparison with silver sulfadiazine ointment. *Burns* 2015;41:125-131.
- Bojadjev C. On the sedative and hypotensive effect of preparations from the plant *calendula officinalis*. *Nauchni Tr Vissh Med Inst Sofiia* 1964;43:15-20.
- Gol'dman II. [Anaphylactic shock after gargling with an infusion of *Calendula*]. *Klin Med (Mosk)* 1974;52:142-143.
- Lagarto A, Bueno V, Guerra I, Valdés O, Vega Y, Torres L. Acute and subchronic oral toxicities of *Calendula officinalis* extract in Wistar rats. *Exp Toxicol Pathol* 2011;63:387-391.
- Shipochliev T. [Uterotonic action of extracts from a group of medicinal plants]. *Vet Med Nauki* 1980;18:94-98.

24. Yilmaz HG, Tacyildiz IH, Keles C, Gedik E, Kilinc N. Micronized purified flavonoid fraction may prevent formation of intraperitoneal adhesions in rats. *Fertil Steril* 2005;84(Suppl 2):1083-1088.
25. Ellis H. The clinical significance of adhesions: focus on intestinal obstruction. *Eur J Surg Suppl* 1997;5-9.
26. Ha HK, Park CH, Kim SK, Chun CS, Kim IC, Lee HK, Shinn KS, Bahk YW. CT analysis of intestinal obstruction due to adhesions: early detection of strangulation. *J Comput Assist Tomogr* 1993;17:386-389.
27. McEntee G, Pender D, Mulvin D, McCullough M, Naeeder S, Farah S, Badurdeen MS, Ferraro V, Cham C, Gillham N, et al. Current spectrum of intestinal obstruction. *Br J Surg* 1987;74:976-980.
28. Van Der Krabben AA, Dijkstra FR, Nieuwenhuijzen M, Reijnen MM, Schaapveld M, Van Goor H. Morbidity and mortality of inadvertent enterotomy during adhesiotomy. *Br J Surg* 2000;87:467-471.
29. Liakakos T, Thomakos N, Fine PM, Dervenis C, Young RL. Peritoneal adhesions: etiology, pathophysiology, and clinical significance. Recent advances in prevention and management. *Dig Surg* 2001;18:260-273.
30. Kennedy R, Costain DJ, McAlister VC, Lee TD. Prevention of experimental postoperative peritoneal adhesions by N,O-carboxymethyl chitosan. *Surgery* 1996;120:866-870.
31. Arung W, Meurisse M, Detry O. Pathophysiology and prevention of postoperative peritoneal adhesions. *World J Gastroenterol* 2011;17:4545-4553.
32. Reijnen MM, Skrabut EM, Postma VA, Burns JW, van Goor H. Polyanionic polysaccharides reduce intra-abdominal adhesion and abscess formation in a rat peritonitis model. *J Surg Res* 2001;101:248-253.
33. Orçan S, Seven A, Isık H, Timur H, Caydere M, Ustün H, Batıloglu S. Resveratrol inhibits postoperative adhesion formation in a rat uterine horn adhesion model. *Hum Fertil (Camb)* 2012;15:217-220.
34. Oncel M, Remzi FH, Connor J, Fazio VW. Comparison of cecal abrasion and multiple-abrasion models in generating intra-abdominal adhesions for animal studies. *Tech Coloproctol* 2005;9:29-33.
35. Diamond MP, Linsky CB, Cunningham T, Constantine B, diZerega GS, DeCherney AH. A model for sidewall adhesions in the rabbit: reduction by an absorbable barrier. *Microsurgery* 1987;8:197-200.
36. Bakkum EA, Van Blitterswijk CA, Dalmeijer RA, Trimbos JB. A semiquantitative rat model for intraperitoneal postoperative adhesion formation. *Gynecol Obstet Invest* 1994;37:99-105.
37. Banasiewicz T, Horbacka K, Karoń J, Malinger S, Antos F, Rudzki S, Kala Z, Stojcev Z, Kössi J, Krokowicz P. Preliminary study with SprayShield™ Adhesion Barrier System in the prevention of abdominal adhesions. *Videochir Inne Tech Maloinwazjne* 2013;8:301-309.
38. Blauer KL, Collins RL. The effect of intraperitoneal progesterone on postoperative adhesion formation in rabbits. *Fertil Steril* 1988;49:144-149.
39. Hellebrekers BW, Trimbos-Kemper GC, Van Blitterswijk CA, Bakkum EA, Trimbos JB. Effects of five different barrier materials on postsurgical adhesion formation in the rat. *Hum Reprod* 2000;15:1358-1363.
40. Emre A, Akin M, Isikgonul I, Yuksel O, Anadol AZ, Cifter C. Comparison of intraperitoneal honey and sodium hyaluronate-carboxymethylcellulose (Seprafilm™) for the prevention of postoperative intra-abdominal adhesions. *Clinics (Sao Paulo)* 2009;64:363-368.