



Giant Epidermal Cyst Unusually Located in Perianal Region

Alışılmadık Bir Şekilde Perianal Bölge Yerleşimli Dev Epidermal Kist

© Hüseyin Taş¹, © Şahin Kaymak², © Rahman Şenocak², © Emin Lapsekili²

¹İzmir Katip Çelebi University Faculty of Medicine, Atatürk Training and Research Hospital, Department of General Surgery, İzmir, Turkey

²Gülhane Training and Research Hospital, Clinic of General Surgery, Ankara

ABSTRACT

Epidermal cysts are a subset of epithelial inclusion cysts, which are common benign skin lesions. In general, they are usually located on the face, neck, or trunk. However, they may form on any part of the body and occasionally occur in the perianal area. These lesions tend to grow over time and in rare cases can become infected. Total excision is the preferred method of treatment. Definitive diagnosis is made only by histopathological examination. The differential diagnosis of perianal cyst should include hemorrhoids, tailgut cysts, anal canal cysts, retrorectal/presacral cysts, teratomas, and dermoid cysts. Here, we present a rare case of very large perianal epidermal cyst in a male patient who received medical treatment for a diagnosis of hemorrhoids and underwent surgical excision when his symptoms did not improve.

Keywords: Epidermal cyst, surgery, perianal involvement

ÖZ

Epidermal kistler, yaygın benign deri lezyonları olan epitel inklüzyon kistlerinin bir alt grubudur. Genellikle yüz, boyun veya gövdede bulunurlar, ancak vücudun herhangi bir yerinde yerleşebilirler ve perianal bölgede nadiren görülürler. Zamanla büyüme eğiliminde olan bu lezyonlar nadiren enfekte olurlar. Total eksizyon tercih edilen tedavi yöntemidir. Kesin tanı sadece histopatolojik inceleme ile konulur. Perianal kistin ayırıcı tanısında hemoroid, tailgut kistleri, anal kanal kistleri, retrorektal/presakral kistler, teratomlar ve dermoid kistler düşünülmelidir. Burada, hemoroid teşhisi konarak medikal tedavi altına alınmış ve şikayetlerin geçmemesi üzerine cerrahi eksizyon ile tedavi edilmiş nadir karşılaşılan ve büyük boyutlara ulaşmış perianal yerleşimli epidermal kist olgusu sunulmaktadır.

Anahtar Kelimeler: Epidermal kist, cerrahi, perianal tutulum

Introduction

Cystic masses can be seen anywhere in the body, including the anal region. Epidermal cysts are also available among these cystic masses. Epidermal cyst which is commonly benign lesions is a subset of epithelial inclusion cysts. Firstly, it was reported as a proliferating epidermal cyst by Jones¹ in 1966. Although epidermal cysts usually appear on the scalp, it has also been reported to be seen in neck, eyes, ears, lips, oral cavity, fingers, hands, hips, thighs, vulva, mons pubis and upper and lower limbs.^{2,3} However, perianal involvement is considerably rare. They are thought to occur with developmental disorder of the sebaceous glands, the progression of epidermis into the dermis layer or duct blockage. Misplacement of ectodermal

structure during embryonic fusion stage is also implicated in the etiology. We present a rare epidermal cyst located in perianal region approximately 6 cm in size.

Case Report

A 21-year-old young man was admitted to clinic with a painless mass but an increasing pain while sitting in the anal area. The mass had grown over the last 5 years and had no association of fever, and he was treated medically several times and underwent thrombectomy with a diagnosis of thrombosed hemorrhoids. His baseline laboratory findings were within normal limits. On his physical examination by the knee-elbow position, smooth mobile mass, approximately



Address for Correspondence/Yazışma Adresi: Şahin Kaymak MD

Gülhane Training and Research Hospital, Clinic of General Surgery, Ankara, Turkey

Phone: +90 532 333 41 14 E-mail: sahinkaymak@hotmail.com ORCID ID: orcid.org/0000-0003-4717-5791

Received/Geliş Tarihi: 23.08.2017 Accepted/Kabul Tarihi: 20.10.2017

6x4 cm in size was observed at 6 o'clock in the perianal area (Figure 1). There were no palpable masses at rectal examination. Ultrasound depicted a well-defined, 6x4x5 cm in diameter, oval, hypoechoogenic subcutaneous mass with posterior acoustic enhancement, extending to the deeper perianal tissues. There is no vascularisation on Doppler ultrasonography (USG). The patient was taken to prone position following spinal anesthesia, and the cystic mass was totally excised through the incision made by approximately 2 cm away from the anal verge. (Figure 2, 3). The lesion originated from the deep layers of external anal sphincters. Having sent to histopathological evaluation, cystic mass was reported as epidermal cysts (Figure 4a, b, c). The approval of the patient and the ethics committee was obtained.

Discussion

Cystic masses can occur anywhere in the body, including in the skin of the anal region. Epidermal cysts arising in the pelvis or perineum are very rare. Most of these cases are retro-rectal or presacral. However, the involvement of the perianal region is quite rare, with less than 10 case reports in the literature. Benign perianal masses are rarely seen especially in female patients (Table 1).^{4,5,6,7,8,9} Epidermal cysts are the most common benign skin lesions. They are seen most commonly in the face, neck or body,¹⁰ however, involvement of the perianal region is very rare. It is believed to occur due to developmental disorders of sebaceous glands,

obstruction of the ducts or extension of the epidermis into the dermis and proliferation.¹¹ The last two etiologies are mostly secondary to trauma. However, some cases may also occur without any cause. In addition, they may arise as a part of Gardner syndrome,¹² which is an autosomal dominant disorder associated with intestinal neoplasms, osteomas, epidermal cysts and thyroid nodules. This patient had a story of external hemorrhoid cushions that thromboses from time to time in the anal region. In patients antecedently having a story of thrombectomy, this intervention could cause the epidermis to progress into the dermis. Epidermal cysts are generally less than 5 cm in diameter. Greater than 5 cm are called large or giant epidermal cysts.¹⁰ In this case, the size of

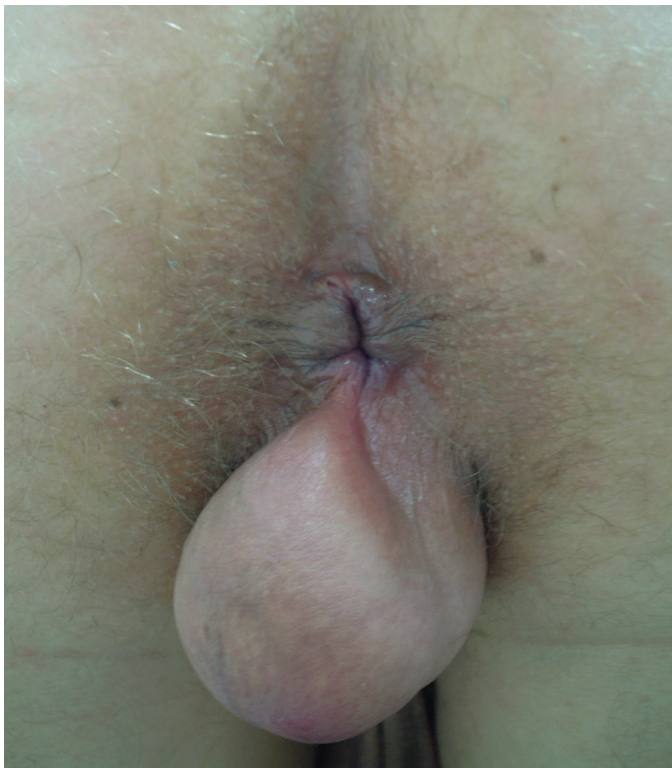

Figure 1. The physical appearance of the lesion

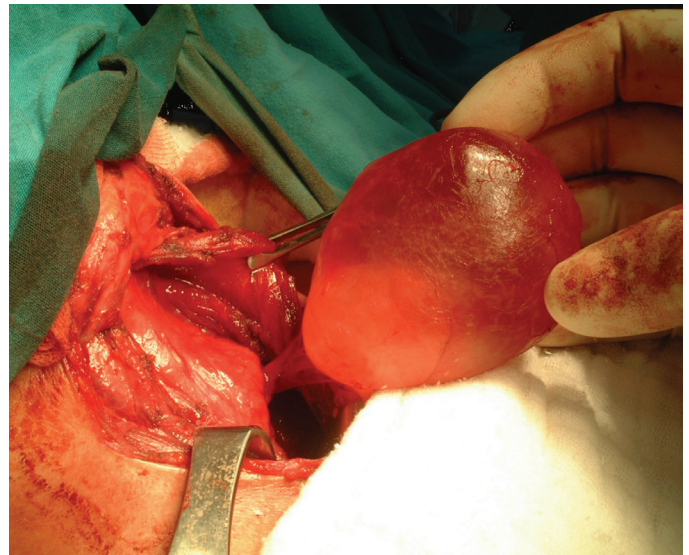


Figure 2. Intraoperative view of the cyst. Cystic mass at deep layers of external anal sphincters

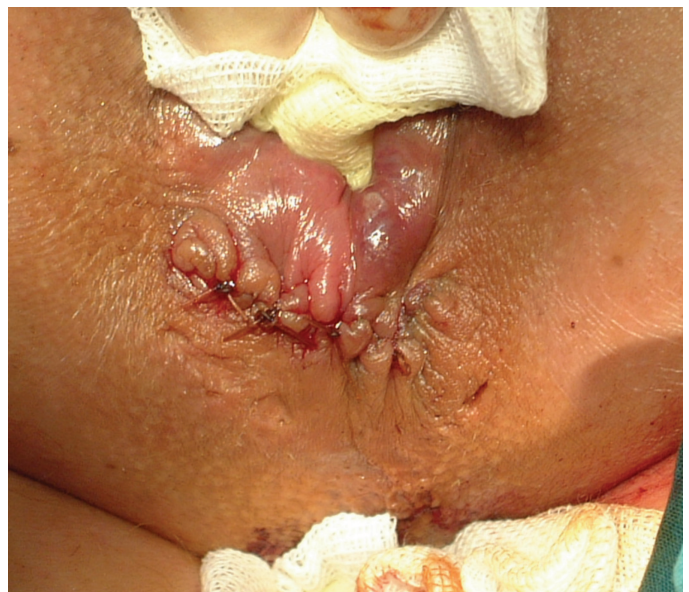

Figure 3. Appearance after excision

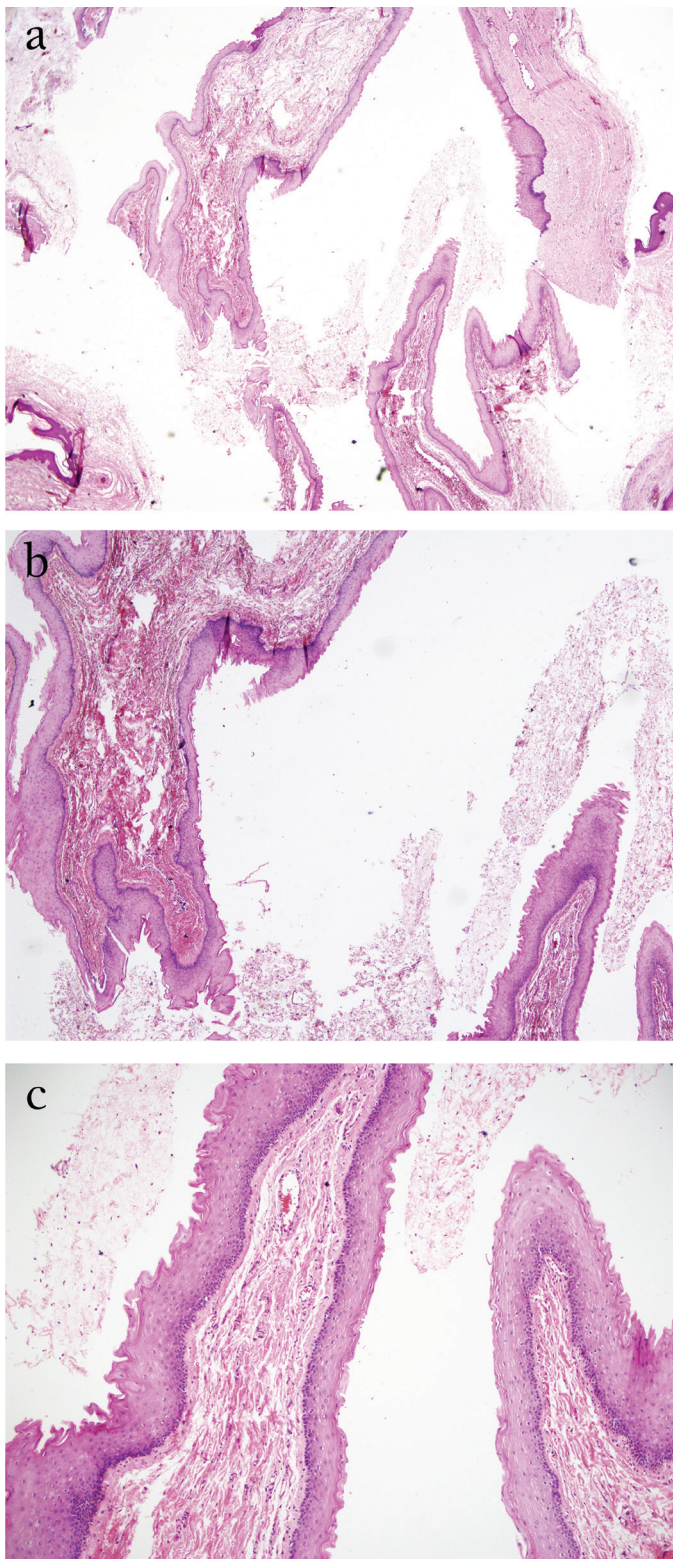


Figure 4. Histopathologic examination revealed a non-neoplastic lesion depicting with minimal keratinization covered with stratified squamous epithelium. Features showing neoplastic growth and/or malignancy are not seen. The lesion was diagnosed as epidermal cysts. a) Microscopic appearance of cysts under 20 \times magnification, b) Microscopic appearance of the cyst under 40 \times magnification, c) Microscopic appearance of the cyst under magnification 100 \times

the cyst was measured 6 cm, thus it was assessed as a giant epidermal cyst. Although they are the most common benign mass of the skin, the placement of the perianal region is very rare. In literature review, any publications except for a few case reports were encountered (Table 1).^{4,5,6,7,8,9} Epidermal cysts are mostly asymptomatic; however, when infected or gave evidence, they lead to compression of the surrounding tissue.¹³ These lesions with tending to grow over time rarely become infected. A small cyst can grow over time; therefore can be turned into a giant cyst.¹⁴ In this case, a 5-year history, treatment history for external hemorrhoids and thrombectomy operations at once were present, and then the patient described a slow-growing mass in the perianal region. A definite diagnosis and the distinction with other pathologies considered in the differential diagnosis is made by only pathological examination. Hemorrhoids, perianal abscess, tailgut cysts, anal canal cysts, retrorectal/presacral cysts, teratomas and dermoid cysts, anal skin cancer should be considered in the differential diagnosis of perianal cysts.^{13,15} In histopathological examination, keratinizing squamous epithelium covered with lamellar layer is diagnostic. In this case, diagnosis of epidermal cysts was made after histopathological examination. Furthermore, pelvic computed tomography (CT), transrectal endosonography, USG or magnetic resonance imaging (MRI) are useful for showing the relationship between the environment and the contents of the cyst tissue.¹⁶ In addition, a CT or MRI of the pelvic cystic mass in the perianal region may be helpful in distinguishing between the anal canal cancer and rectal cancer. There are no laboratory tests for helping diagnose. In this case, a diagnostic superficial tissue ultrasound was used, which showed a 6 cm cystic mass. There was no invasion into nearby surrounding tissue and no vascularisation on USG. Total excision is the preferred treatment method. Asymptomatic epidermal inclusion cysts do not need treatment. When becoming symptomatic, treatment consists of wide excision, since there is some risk of recurrence. Malignant degeneration in epidermal inclusion cysts is very rare.⁸ History, physical examination and ultrasonographic findings did not suggest an abscess or tumor in this case. It is very important that integrity of cyst not be disrupted and perforated during excision. The preservation of the anal sphincter during the process is also important in cases of localized perianal region. The cyst was completely excised without damaging sphincter and being disrupted. Epidermal cysts occur very rarely in the perianal region, but can develop anywhere on the skin. Benign and malignant masses located in perianal region should be considered in the differential diagnosis in these patients. Cysts must be fully excised without disrupting the integrity of the cyst and damaging the sphincter.

Table 1. Details of the reported cases of perianal epidermal cyst along with their treatment in literature

Study no	Authors, year	Age	Sex	Investigations	Diameter of the mass (mm)	Presentation	Treatment
1	Kesici et al. ⁴	47	Female	USG	56x45	Painless mass	Excision under spinal anesthesia
2	Nicolay et al. ⁵	51	Female	USG, MR	-	Painful mass	Excision
3	Akyüz et al. ⁶	44	Male	CT	70x50	Painless mass	Excision under spinal anesthesia
4	Lake et al. ⁷	41	Male	MR	60x60	Painless mass	Excision
5	Temiz et al. ⁸	68	Male	TRUS	45x50	Painless mass	Excision under spinal anesthesia
6	Temiz et al. ⁸	27	Female	USG, CT, MR	55x20	Painful mass	Excision
7	Sritharan et al. ⁹	20	Male	-	15x10	Painless lump	Excision
*	Tas et al.	21	Male	USG	60x45	Painless mass	Excision under spinal anesthesia

*Present case

USG: Ultrasonography, CT: Computerized tomography, MR: Magnetic resonance, TRUS: Transrectal endosonography

Ethics

Informed Consent: Consent form was filled out by the patient.

Peer-review: Internally peer-reviewed.

Authorship Contributions

Surgical and Medical Practices: H.T., Concept: Ş.K., Design: Ş.K., E.L., Data Collection or Processing: H.T., Analysis or Interpretation: R.Ş., Literature Search: R.Ş., E.L., Writing: Ş.K., E.L.

Conflict of Interest: No conflict of interest was declared by the authors.

Financial Disclosure: The authors declared that this study received no financial support.

References

- Jones EW. Proliferating epidermoid cyst. *Arch Dermatol* 1966;94:11-19.
- Sau P, Graham JH, Helwig EB. Proliferating epithelial cysts. Clinicopathological analysis of 96 cases. *J Cutan Pathol* 1995;22:394-406.
- Ye J, Nappi O, Swanson PE, Patterson JW, Wick MR. Proliferating pilar tumors: a clinicopathologic study of 76 cases with a proposal for definition of benign and malignant variants. *Am J Clin Pathol* 2004;122:566-574.
- Kesici U, Sakman G, Mataraci E. Retrorectal/Presacral Epidermoid Cyst: Report of A Case. *Eurasian J Med* 2013;45:207-210.
- Nicolay S, De Schepper A, Pouillon M. Epidermal inclusion cyst of the perianal region. *JBR-BTR* 2014;97:166-167.
- Akyüz C, Fatih N, Peker KD, Uzun O, Duman M, Polat E, Yol S. A Rare Case: A Large Perianal Epidermal Cyst. *Bakırköy Tıp Dergisi* 2014;10:182-184.
- Lake S, Engledow A, Cohen C. An Unusual Perineal Swelling: A Cyst Between the Sphincters. *J Surg Case Rep* 2010;2010:2.
- Temiz M, Aslan A, Hakverdi S, Canbolant E, Diner G. Giant Benign Epidermal Perianal Cysts: Report of Two Cases. *Turk J Colorectal Dis* 2008;3:146-147.
- Sritharan K, Ghani Y, Thompson H. An unusual encounter of an epidermoid cyst. *BMJ Case Rep* 2014:2014.
- Basterzi Y, Sari A, Ayhan S. Giant epidermoid cyst on the forefoot. *Dermatol Surg* 2002;28:639-640.
- Polychronidis A, Perente S, Botaitis S, Sivridis E, Simopoulos C. Giant multilocular epidermoid cyst on the left buttock. *Dermatol Surg* 2005;31:1323-1324.
- Lin SH, Yang YC, Chen W, Wu WM. Facial epidermal inclusion cysts are associated with smoking in men: a hospital-based case-control study. *Dermatol Surg* 2010;36:894-898.
- Krones CJ, Peiper C, Griefi ngholt H, Schumpelick V. Tailgut cyst. Rare differential diagnosis of retrorectal tumors. *Chirurg* 2002;73:1123-1126.
- Elder DE, Elenitsas R, Johnson B Jr, Loffreda M, Miller J, Miller OF III. Atlas and synopsis of Lever's histopathology of the skin. 10th ed. Philadelphia; Lippincott Williams & Wilkins, 2008.
- Kulaylat MN, Doerr RJ, Neuwirth M, Satchidanand SK. Anal duct/gland cyst: report of a case and review of the literature. *Dis Colon Rectum* 1998;41:103-110.
- Dahan H, Arrivé L, Wendum D, Docou le Pointe H, Djouhri H, Tubiana JM. Retrorectal developmental cysts in adults: clinical and radiologic histopathologic review, differential diagnosis, and treatment. *Radiographics* 2001;21:575-584.